

# Platelet-derived Factor Concentrates with Hyaluronic Acid Scaffolds for Treatment of Deep Burn Wounds

Takanobu Mashiko, MD\*†  
 Toshiharu Minabe, MD\*  
 Tomomi Yamakawa, MD\*  
 Jun Araki, MD†  
 Hitomi Sano, MD‡  
 Kotaro Yoshimura, MD†§

**Summary:** A deep burn wound is a critical condition that generally necessitates vascularized tissue coverage. We performed the injection of platelet-derived factor concentrates combined with non-cross-linked hyaluronic acid scaffolds for 2 patients with critical burn wounds with bone and tendon exposure and achieved successful healing. Hyaluronic acid was considered to have served as a controlled-release carrier of platelet-derived factors, being clinically effective for the treatment of deep burn wounds. (*Plast Reconstr Surg Glob Open* 2016;4:e1089; doi: 10.1097/GOX.0000000000001089; Published online 26 October 2016.)

A deep burn wound is very difficult to treat and usually requires reconstruction using vascularized tissues. Regenerative medicine has begun to adopt new treatments for such nonhealing ulcers, and platelet-rich plasma (PRP) is one of the easiest-to-use methods as it can be harvested from the patient's own blood and thus completely avoids immune rejection and allergic reaction.<sup>1</sup> We previously reported a preparation protocol for platelet-derived factor concentrate (PFC), which achieved platelet and platelet-derived growth factor (PDGF)-BB concentrations 20 and 200 times higher than those found in whole blood, respectively.<sup>2</sup> Herein, we report the clinical outcomes in 2 patients with critical burn wounds with bone and tendon exposure, who were successfully treated by injection of PFC in combination with hyaluronic acid (HA) scaffolds.

## METHODS AND RESULTS

A 52-year-old man received a severe left facial wound after a heat-press injury. He promptly received debridement of the wound (Fig. 1A), and 6 days after, skin graft

into the lateral region, which had a good wound bed, and free perifascial areolar tissue graft into the medial region, where bone was exposed, were performed. Although skin graft survival was confirmed 1 week post-operatively, the perifascial areolar tissue graft was not accepted, and bone (partly becoming sequestrum) became exposed again. Therefore, after approval by the institutional review board, we initiated treatment using PFC, which was prepared according to the previous protocol,<sup>2</sup> and also administered HA scaffolds. Briefly, whole blood was drawn from the patient and centrifuged at 270g for 10 minutes. The isolated PRP layer was centrifuged again at 2300g for 10 minutes to spin down platelets. The platelet-poor plasma was partially removed and replaced with a one-tenth volume of phosphate-buffered saline for noncoagulating PFC. Platelet activators such as thrombin were not added, because they will be released from the surrounding tissue. After the platelets were resuspended, 0.6 mL of PFC and 0.4 mL of non-cross-linked HA (Artz, Seikagaku Corporation; Tokyo, Japan) were mixed and injected into the surface of the ulcer of the medial region through a 30-gauge needle once a week (see video, **Supplemental Digital Content 1**, which displays the injection technique, <http://links.lww.com/PRSGO/A281>). After 3 sessions of treatment, healthy granulation tissue and per ulcer epithelization were noted (Fig. 1B). The remaining ulcer epithelized within several weeks, and no recurrence was observed as of 1-year follow-up.

From the \*Department of Plastic Surgery, Saitama Medical Center, Saitama Medical University, Saitama, Japan; †Department of Plastic Surgery, School of Medicine, University of Tokyo, Tokyo, Japan; ‡Department of Plastic, Reconstructive and Aesthetic Surgery, Nippon Medical School, Tokyo, Japan; and §Department of Plastic Surgery, Jichi Medical University, Tochigi, Japan.

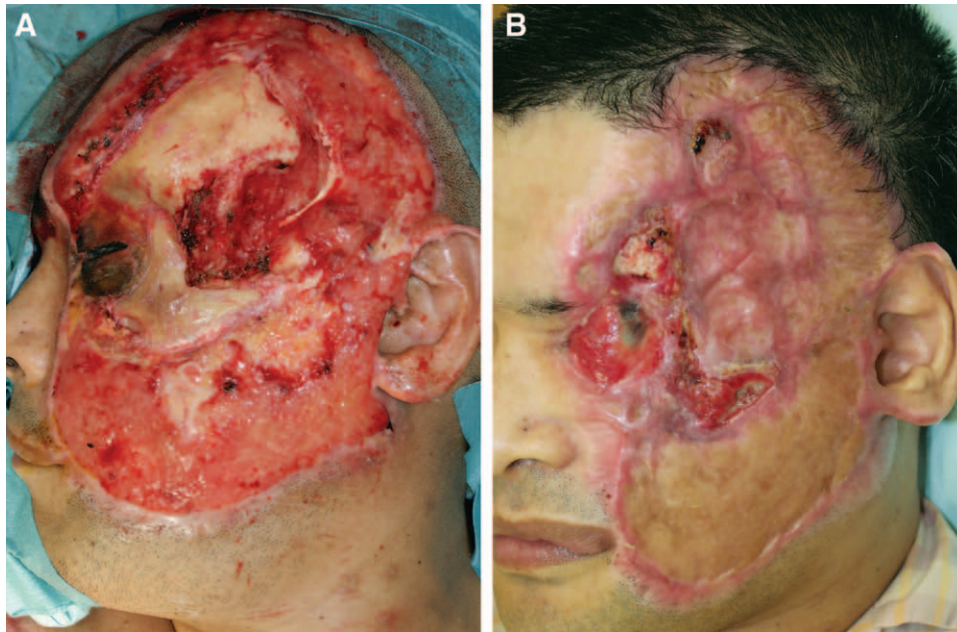
Received for publication July 04, 2016; accepted August 29, 2016. Supported by JSPS KAKENHI, Grant Number 16J01745.

Copyright © 2016 The Authors. Published by Wolters Kluwer Health, Inc. on behalf of The American Society of Plastic Surgeons. All rights reserved. This is an open-access article distributed under the terms of the Creative Commons Attribution-Non Commercial-No Derivatives License 4.0 (CCBY-NC-ND), where it is permissible to download and share the work provided it is properly cited. The work cannot be changed in any way or used commercially without permission from the journal.

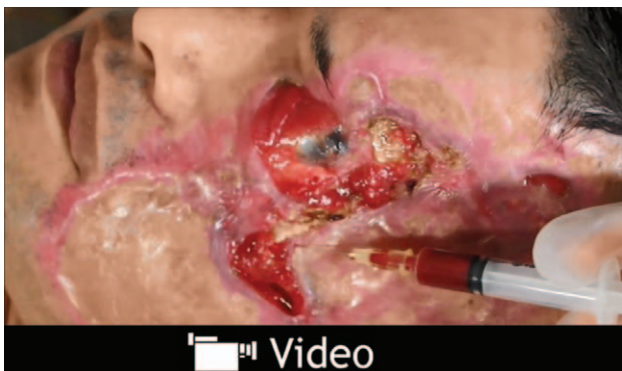DOI: 10.1097/GOX.0000000000001089

**Disclosure:** The authors have no financial interest to declare in relation to the content of this article. The Article Processing Charge was paid for by the authors.

Supplemental digital content is available for this article. Clickable URL citations appear in the text.



**Fig. 1.** A, Intraoperative facial view after debridement on the day of heat-press injury. The frontal bone and zygomatic bone were exposed. B, Posttreatment facial view at 1 month. Although the nonvascularized tissue graft survived in the lateral region, it did not survive in the medial region. Three sessions of PFC treatment led to partial epithelization of the deep ulcer and healthy granulation.



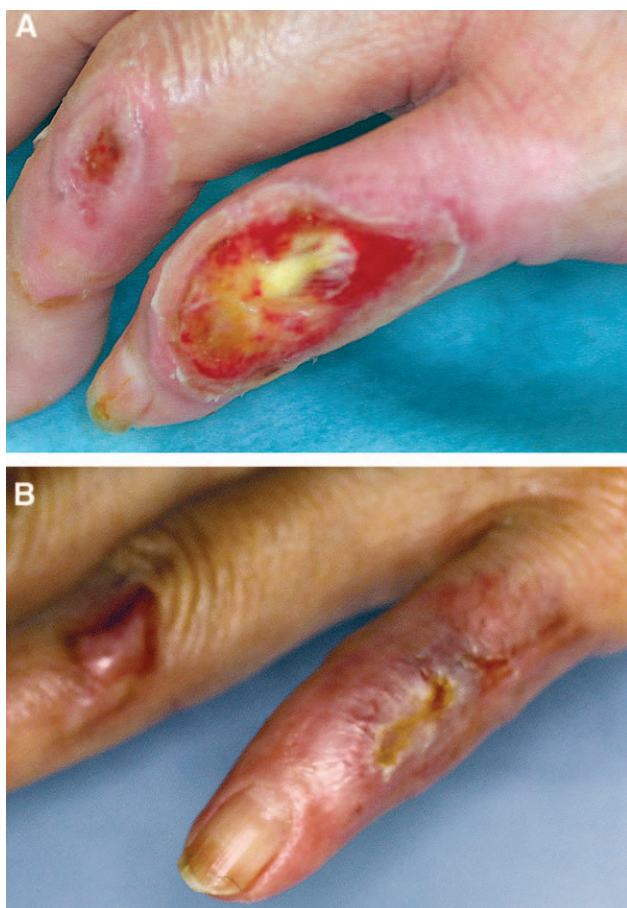**Video Graphic 1.** See video, Supplemental Digital Content 1, which displays an injection into the surface of the ulcer of the medial region through a 30-gauge needle. This is performed once a week, <http://links.lww.com/PRSGO/A281>.

A 61-year-old woman sustained a burn caused by heated oil to her left hand. She was diagnosed with a superficial second-degree burn of the fourth finger and third-degree burn of the fifth finger. She received debridement for the fifth finger on day 3 after injury, resulting in tendon exposure (Fig. 2A), and we began treatment using PFC-HA. After preparation in the same manner as described above, the weekly injection of 0.3 mL of PFC combined with 0.2 mL of non-cross-linked HA was performed into the wound surface of the fifth finger. After 2 sessions of treatment, the wound had almost completely closed, whereas the fourth finger healed with standard conservative treatment but left a hypertrophic scar (Fig. 2B).

## DISCUSSION

PDGFs are released during the clotting cascade and acts as an initiator of wound healing.<sup>3</sup> PRP contains various bioactive substances including PDGF, transforming growth factor- $\beta$ , and epidermal growth factor,<sup>2</sup> and its beneficial influence on tissue remodeling is attributed to mesenchymal cell recruitment and proliferation resulting in vascularization, extracellular matrix synthesis, and granulation.<sup>1,4</sup> PRP not only aids in the healing of a greater range of wounds but also shortens the time to healing<sup>1</sup>; however, the therapeutic use of PRP is still controversial because of the lack of standardized protocols and indications.

Standard treatment for deep burn wounds with exposed bone or tendons is vascularized tissue coverage; however, we could successfully treat 2 patients by the injection of PFC with HA scaffolds. Our protocol required 2 or 3 sessions of treatment, as the advantageous effects from PDGFs are most likely to occur when they are repeatedly applied to the wound bed.<sup>1</sup> PFC prepared by our protocol has a higher PDGF-BB concentration (157.9 ng/mL on average) than the PRP concentration in previous reports,<sup>2</sup> and it is also highly aqueous because of the lack of fibrinogen, which is discarded together with platelet-poor plasma. Although fibrin gel may be useful as a carrier of growth factors, it reduces the final concentration, hinders the easy injection of PRP, frequently leads to uncontrollable coagulation, and is not preferable in many clinical situations. In this study, we alternatively used non-cross-linked HA as a scaffold and controlled-release carrier of PFC. We previously demonstrated that HA could be a biological cell scaffold where mesenchymal stem cells could adhere, survive, and proliferate.<sup>5</sup> In addition, HA is as-



**Fig. 2.** A, Intraoperative view, after debridement on the third day after burn injury. The tendon on the extensor digiti minimi was exposed. B, Posttreatment view at 2 weeks. Two sessions of PFC treatment had almost completely healed the ulcer.

sumed to keep PFC around the ulcer and continuously releasing PDGF: as PFC is in a liquid form, its effects must be released slowly.<sup>6</sup> Although further evaluation is necessary, PFC–HA treatment is easy to apply, safe, and an effective choice to heal deep burn wounds that are intractable to conventional conservative treatment, and it may be promising for the treatment of refractory ulcers.

**Takanobu Mashiko, MD**

Department of Plastic Surgery  
Saitama Medical Center  
Saitama Medical University  
1981 Kamoda, Kawagoe  
Saitama 350–8550, Japan  
E-mail: tmashiko-ky@umin.ac.jp

### REFERENCES

1. Sommeling CE, Heyneman A, Hoeksema H, et al. The use of platelet-rich plasma in plastic surgery: a systematic review. *J Plast Reconstr Aesthet Surg.* 2013;66:301–311.
2. Araki J, Jona M, Eto H, et al. Optimized preparation method of platelet-concentrated plasma and noncoagulating platelet-derived factor concentrates: maximization of platelet concentration and removal of fibrinogen. *Tissue Eng Part C Methods* 2012;18:176–185.
3. Anitua E, Andia I, Ardanza B, et al. Autologous platelets as a source of proteins for healing and tissue regeneration. *Thromb Haemost.* 2004;91:4–15.
4. Trapasso M, Spagnolo F, Marchi F, et al. Regenerative surgery for the definitive repair of a vasculitic nonhealing ulcer using platelet-derived growth factors and noncultured autologous cell suspension. *Plast Reconstr Surg Glob Open* 2013;1:1–3.
5. Mineda K, Feng J, Ishimine H, et al. Therapeutic potential of human adipose-derived stem/stromal cell microspheroids prepared by three-dimensional culture in non-cross-linked hyaluronic acid gel. *Stem Cells Transl Med.* 2015;4:1511–1522.
6. Yazawa M, Ogata H, Nakajima T, et al. Basic studies on the clinical applications of platelet-rich plasma. *Cell Transplant.* 2003;12:509–518.